



DENTALAIRE

Meeting and Exceeding the Needs of Veterinary Dentistry since 1988



The 12-Step Cleaning Procedure

Presented by:

**Tony M. Woodward DVM, AVDC
and Dentalaire Products**

17742 Mitchell North, Suite B
Irvine CA 92614
www.dentalaireproducts.com
800.866.6881



www.DentalaireProducts.com | 800.866.6881

Dentalaire Products | 17742 Mitchell North, Suite B Irvine CA 92614

info@dentalaireproducts.com



The first question you might be asking yourself is why even bother implementing a higher level of dental care in your practice? There are a number of reasons for improving the quality of your dental department. The most important reason is that many of your patients are suffering from undiagnosed pain. In my last general practice, approximately 50% of canine and feline patients over five years of age had at least one painful dental problem. Most feline patients over five years of age have at least one Resorptive Lesion (FORL), which can be very painful. Approximately half of your current patients are in need of some level of dental care right now. In addition, periodontal disease has been shown to be associated with pathologic changes in cardiac, hepatic, and renal tissues. In humans, there is a statistical association between periodontal disease and difficult diabetic regulation. This same association may exist in our veterinary patients. Finding and correctly treating these frequently hidden, painful conditions can result in more positive client feedback than the rest of your practice combined.

For years, the standard of care in veterinary dentistry was to remove the calculus visible above the gum line and extract any teeth with increased mobility. This level of care, still common today, can be referred to as “scrape and yank dentistry”. This is a pathetic level of care for the patient, and fails to address most of the treatable painful pathology present in your patients. Teeth with increased mobility have likely been diseased for years. Therefore, the presence of teeth with increased mobility indicates that treatable pathology has probably remained undiagnosed for years. In the author’s practice, increased mobility is one of the least common reasons for treating a tooth. It is much more professionally satisfying to find and treat dental pathology before extraction is required.

Unfortunately, most pets do not show obvious signs when suffering from dental disease. A wild Canid or Felid is not programmed to show any sign of weakness. If they do show weakness, they are moved down the ladder of seniority or singled by a larger predator. Our domestic canine and feline patients behave in the same manner. They do not know that they can do anything about their dental problems, so they just learn to “live” with it. The signs of pain come on very gradually, so the owner frequently associates the pets behavior with just getting older. By contrast, when you treat a dental problem correctly, the owner frequently notices a rapid improvement in the pet’s demeanor. In my opinion, dental disease is the most common reason for a pet to “act older”.

When you proactively look for and treat dental problems, everyone is a winner. The pet benefits because they feel better, act better, and relate better to their owner. The owner benefits because their pet acts better, their breath is not offensive, and so the human-animal bond is strengthened. The practice benefits from owners that are bonded more closely to their pets and improved financial security. There are no losers in this equation!

A well run dental department should provide 15-20% of the gross revenue in a small animal practice. Most practices average only around 3%. Dental disease is the single most overlooked, under-delivered area in veterinary practice.

| PROPHY VS. PERIODONTAL TREATMENT |

One important concept you need to understand is the difference between a “prophy” and “periodontal treatment”. Human patients receive routine dental prophylaxis, designed to prevent the development of periodontal disease. Our patients, in contrast, usually have established periodontal disease and a much higher level of pathology, but pet owners cannot be expected to automatically know this. We rarely provide simple “prophylaxis”. Owners need to be educated that their pet’s treatment is much more involved than a typical cleaning that they themselves might receive. Let them know that the average dog or cat dental cleaning is like cleaning a person’s mouth that did not brush their teeth for a few years.

Veterinarians have been very hesitant about recommending dental treatment until the late stages of disease. Be proactive! How long do you wait to treat a grass awn in the ear canal? More than likely you would recommend treatment, whether or not the patient showed obvious clinical signs. Many owners comment that their pet is “eating OK”, so there must not be a problem. Nothing could be further from the truth. Pets will eat despite the presence of severe dental disease, in many cases swallowing their food whole. You must educate the owner about what the potential problems are, and inform them that these conditions are frequently painful. Half of the dogs and cats in your practice are in need of some level of dental care. In my experience, most dogs and cats over 5 years of age have at least one painful dental problem. Your job is to be the patient’s advocate, and find the problems!!

Common indications for dental treatment include (but are not limited to):

- Gingivitis (red stripe along the gum line, especially upper premolars and molars)
- Accumulation of calculus along the gingival margin
- Asymmetrical calculus accumulation
- Oral malodor- due to pathogenic anaerobic bacteria
- Periodontal pockets- defined as over 1mm deep in a cat or 3 mm deep in a dog
- Altered oral behaviors/ eating difficulties (these are rarely noticed by the owner)
- Any indication of oral discomfort
- Nasal discharge
- Epistaxis
- Oral/facial enlargements
- Draining tracts on the face or gums
- Increased mobility of teeth
- Discolored teeth
- Fractured teeth with exposed dentin
- Fractured teeth with exposed pulp tissue
- Missing teeth
- Malocclusion resulting in trauma to oral soft tissues or dental structures
- Caries (cavities)
- Resorptive lesions (especially in feline patients)
- Orthodontic problems in young patients with deciduous dentition

| The Twelve Basic Steps for Quality Dental Care |

Quality dental care is based upon a methodical process. The 12-step cleaning procedure is the foundation from which proper diagnosis and treatment flow. If you are diligent in applying these steps, your patients will benefit, your clients will notice the difference, and you will be rewarded.

Step 1. Patient History and Physical exam

Patient history and a good general physical exam are important for several reasons. Many times, clues in the patient’s history can lead us to a specific dental lesion. Some systemic diseases can have implications for oral health. Examples include dogs with allergic conditions who wear their incisors down to the pulp chambers when they chew, and animals with a history of abnormal bleeding who continue to bleed after an oral surgical procedure. Pay particular attention to things that might effect anesthesia, such as cardiopulmonary function. Other items worthy of note include the presence of any oral/facial enlargements, draining tracts, lymph node enlargement, altered eating behaviors, a history of chewing on fences or frantic behavior in response to thunderstorms.

Step 2. Initial oral survey

The initial oral survey can be done prior to anesthesia in a cooperative patient, or immediately after anesthetic induction. You should try to give the entire oral cavity a “once over” to give you an idea about what the case might entail. Specific things to look for include the head type (long vs short facial structure), any occlusal abnormalities, ulcerations of the gingival or labial tissues, lesions on the palate, lesions under the tongue, fractured teeth, discolored teeth, increased mobility, caries or resorptive lesions, furcation exposure, odor, pain on manipulation, TMJ crepitus, missing teeth, super-erupted teeth, expansion of alveolar bone around teeth, or any type of oral tissue enlargement.

Step 3. Supragingival Calculus removal

Removal of the supragingival calculus (above the gum line) **is the most visible part** of the procedure for the owner, but is **the least important part for the patient's dental health**. There are many acceptable methods for supragingival calculus removal. ***It is important to realize that this step is all a groomer or lay person can perform without anesthesia.*** The idea that a quality dental cleaning can be done on awake patient is ludicrous. People who attempt non-anesthetized cleaning procedures are unable to assess the extent of disease, are not equipped to take dental radiographs, and are not trained to make correct diagnoses. In other words, they cannot find and treat the painful problems almost always present in the oral cavity. If there are some areas of pain (which there usually are) the patient is subjected to discomfort as these areas are cleaned. This type of procedure is actually worse than doing nothing at all, because the owner is lulled into thinking that their animal's problem is taken care of, when in fact it is not. The teeth look cleaner, but the most important parts of the 12-step procedure have been ignored. The patient needs professional care, and the veterinarian is the person to provide that care.

Supragingival calculus removal usually is accomplished with a combination of power equipment followed by hand scaling. Hand scaling can be very effective, but is fatiguing and time-consuming when used as the sole method of calculus removal. The common hand instruments used are tartar forceps for cracking loose large accumulations of calculus, and hand scaling instruments. Hand scaling instruments consists of scalers and curettes. **Scalers** have sharp tips and are designed to be used only above the gumline. The sharp tip facilitates cleaning of small areas and grooves present in some teeth. **Curettes** have a blunt “toe” and curved back, and may be used above and below the gum line. Most operators save their curettes for fine work below the gum line.

The majority of supragingival calculus removal is accomplished utilizing power equipment. Scaling with power equipment should be considered a contaminated procedure. All power equipment creates aerosolized bacteria, which can travel several meters in the air. To help decrease aerosolized bacteria, start by brushing the mouth with dilute Chlorhexidine solution (0.12%). This solution can be made by adding 60 ml of 2% Chlorhexidine solution (not scrub) to one liter of water/saline (227 ml per Gallon). Mask, eye, and hand protection for the operator are recommended to decrease bacterial exposure. Protection for patient should include covering the eyes and placing gauze sponges in the pharynx to help prevent aspiration of calculus and fluid laden with microorganisms.

There are a number of different types of power scaling equipment available. Below are some specific comments on the different types and their characteristics.

1. **Rotary instrument** on high-speed (Roto-Pro) - not recommended, very damaging
2. **Sonic scalers** - requires air compressor, high pitched whine
3. **Ultrasonic scalers** - All types work well Tip frequency
 - a. Magnetostrictive (“stack”) Figure-8 tip motion (25-30 KHZ)
 - b. Piezoelectric (crystal) linear tip motion (20-45 KHZ)
 - c. Magnetostrictive (“Ferrite rod”)/Odontoson) circular tip motion (42 KHZ)
4. **Hydraulic Scalers** - “sandblasters”- messy, difficult to control, can cause sodium overload if using sodium bicarbonate

Step 3. Supragingival Calculus removal - cont'd

All types of sonic and ultrasonic power equipment are effective and all can be damaging when used improperly. Some specific tips for proper use include:

1. Use only the side of the tip. This is the most effective and least damaging area of the instrument to place on the teeth.
2. Scale for less than 15 seconds per tooth. It is possible to kill a tooth with ultrasonic trauma. If an individual tooth is going to take longer to scale, leave that tooth and come back to it in 1-2 minutes.
3. A light touch is actually more effective than hard pressure. Too much pressure can stall the tip and decrease the effectiveness of the scaler.
4. Be gentle. Gingival tissues are very delicate.
5. Take care under the gum line. You need special periodontal tips on your power equipment to use subgingivally
6. In general, higher frequencies are quieter and provide smaller excursions of the tip
7. Water spray is essential for cooling and flushing debris. Adjust the water spray until a fine “halo” of water is produced.
8. All power equipment aerosolizes debris and bacteria. Take precautions as detailed above.
9. Replace tips and stacks regularly. As the tip wears, the power decreases and you may find yourself constantly turning the power setting up to high. You may also experience overheating of the handpiece, despite adequate water flow. This are indications that the tips and/or stacks may need to be replaced. Piezoelectric scaler tips usually come with a wear guide that is used to track the amount of wear. The tip is held against the guide to indicate when the wear is advanced enough to require tip replacement. A general recommendation would be to replace the scaler tips and/or stacks every 6-9 months in a practice performing five dental cleaning procedures a week.

Step 4. Subgingival cleaning

In contrast to supragingival scaling, subgingival scaling is the least visible part of the procedure for the owner, **but is the most important part of the procedure for the patient**. Subgingival scaling serves to remove calculus, plaque, and toxins from the root surfaces, allowing normal re-attachment of periodontal structures to the root. Subgingival scaling involves a combination of power equipment and hand instruments, and may involve three different steps. All three steps take place more or less at the same time as material is removed from the root surfaces.

1. Subgingival scaling (calculus removal)
2. Root planing (smoothing rough surfaces)
3. Subgingival curettage (soft tissue debridement of the inside of the gingival pocket)

Periodontal disease results from the combined action of oral bacteria and the immune response of the host. These two factors may result in the gradual loss of the supporting structures of the teeth, including attached gingiva, alveolar bone, periodontal ligament and cementum, collectively referred to as “normal attachment”. As this loss occurs, periodontal pockets can form. Pockets are detected by gently placing a periodontal probe under the gingival margin in several locations around the tooth, looking for areas of increased depth. Periodontal pockets are defined as probing depths greater than 1 mm in cats and 2-3mm in dogs. Periodontal pockets allow the collection of plaque, calculus, and foreign material under the gingival margin. As plaque mineralizes to become calculus, the newly formed calculus serves as a plaque retentive surface, more plaque is mineralized and more calculus forms. This cycle of plaque retention and mineralization continues and the pockets become deeper. Eventually this process results in so much loss of the normal attachment that the tooth becomes unsalvageable.

One important consideration in cleaning periodontal pockets is the **depth of the pocket**. Generally speaking, a pocket of up to 5-6mm in depth can be cleaned effectively without using a surgical flap. This is referred to as “**closed root planing**”. In these pockets, a combination of ultrasonic and hand scaling will usually clean the pocket effectively, leading to some re-attachment of tissues to the root surfaces. Pockets up to 5-6 mm deep are a common place to use

Step 4. Subgingival cleaning - cont'd

Doxirobe gel as an adjunct treatment. Doxirobe gel is a combination of Doxycycline and a slowly dissolving polymer. As the polymer dissolves, high levels of Doxycycline are released into the periodontal pocket. The product fights infection, inhibits tissue destruction, and helps keep debris and plaque from filling up the defect. Doxirobe gel is an adjunct treatment for periodontal disease and is not meant to replace thorough cleaning of the root surfaces. It will not sterilize calculus. The most important part of the procedure is to clean the exposed root surface in a thorough fashion. The procedure for closed root planning and using Doxirobe gel is described below.

When the pocket depth is greater than 5-6 mm, effective cleaning requires the use of a surgical flap to expose the pocket surfaces. This is referred to as **“open root planning”**, and is a precise surgical procedure beyond the scope of this class. Open root planing frequently involves bone contouring, augmentation of the bone, and repositioning of the surgical flap. Entire human dental textbooks are devoted to periodontal therapy. A complete explanation of all the facets of periodontal disease and modes of treatment is beyond the scope of this class.

Curettes are hand-scaling instruments that have been designed for use under the gum line. Curettes have a blunt “toe” and a curved back, which makes them less damaging under the gum line. **Scalers** are designed for use above the gingival margin, and can be identified by their sharp tip and triangular crosssection. When used under the gum line, scalers tend to cut and damage the delicate subgingival tissues.

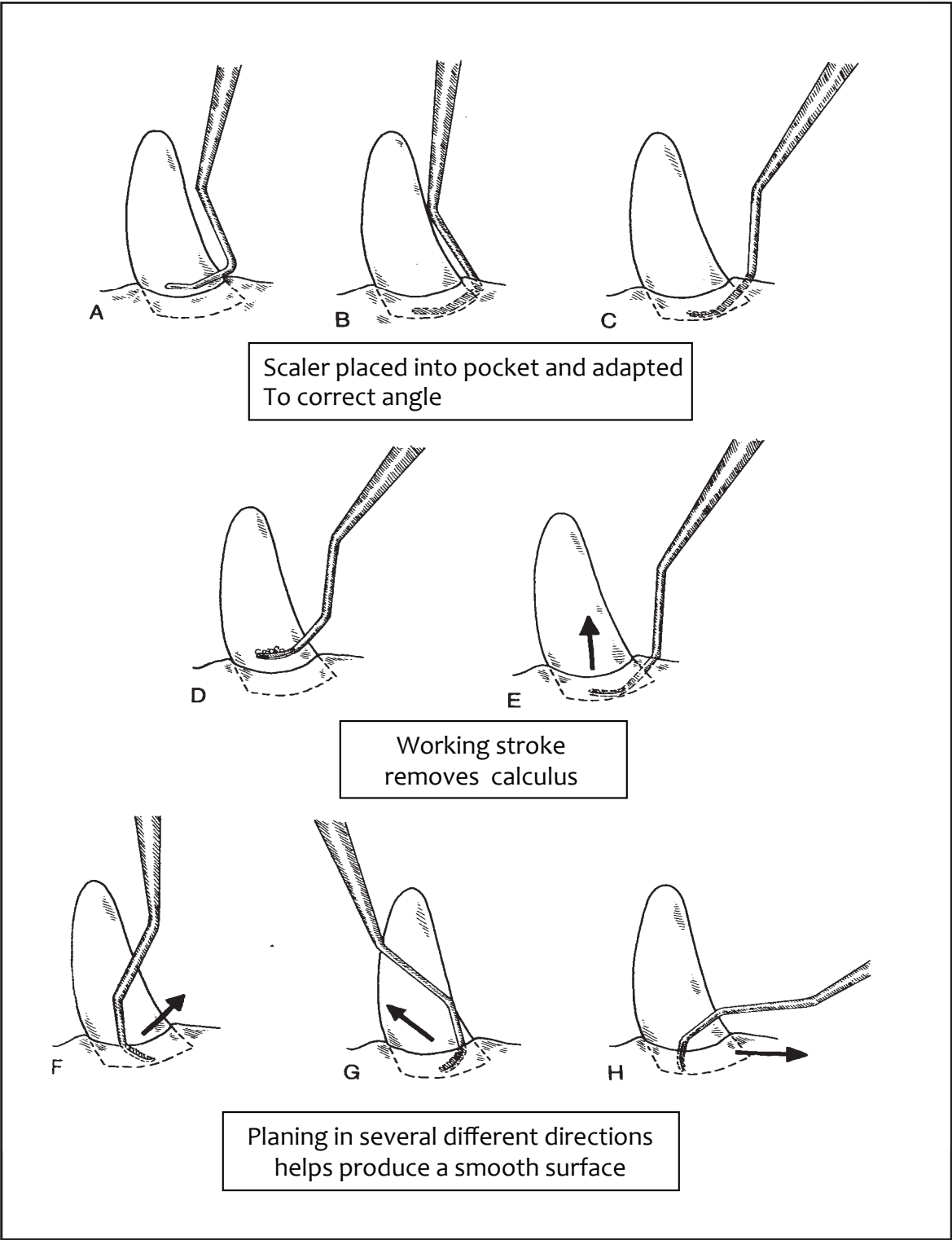
Current thinking suggests that a perfectly smooth root surface is not necessary for re-attachment of gingival tissue to occur. When excessive amounts of root structure (cementum and/or dentin) are removed to achieve a perfectly smooth surface, increased patient sensitivity and delayed healing may result. This realization has lead to increased use of ultrasonic equipment under the gum line. Recently, the use of ultrasonic equipment has gained popularity for subgingival scaling. This involves the use of thin periodontal tips, which are now available for most almost all scalers. Common acronyms for this procedure are **“PerioBUD”** (Periodontal Bacterial Ultrasonic Debridement) and **“UPL”** (Ultrasonic Periodontal Lavage). The procedure is very effective at removing calculus, disrupting plaque, and destroying bacteria via ultrasonic energy. The ultrasonic equipment is best used with an antibacterial lavage solution, typically .12% Chlorhexidine. The special periodontal tip is placed into the periodontal pocket on low power, and the side of the tip is gently swept along the root surfaces. Compared to hand scaling, PerioBUD results in less removal of cementum and/or dentin, and improved healing. The author typically uses ultrasonic instrumentation for the majority of the work, followed by gentle hand scaling to remove any material missed by the ultrasonic equipment.

Closed root planning Procedure (possibly with Doxirobe gel placement):

As mentioned above, **Closed Root Planing** is used when a periodontal pocket depth measures 5-6 mm or less. All periodontal pockets are first radiographed to ensure that the tooth does not have any pathology that would modify your treatment options or preclude treatment.

The initial step is to use the ultrasonic “thin tip” insert with your ultrasonic scaler as described above. This will remove most of the calculus and diseased cementum from the root surfaces. Next, root surface is scaled and smoothed using hand scaling curettes. The curette is placed into the periodontal pocket, adapted to the root surface, and pulled out during the working stroke. Multiple overlapping strokes and multiple directions result in a smooth root surface, free of plaque, calculus, and toxic material. See below for a diagram showing correct use of curettes under the gum line. Note the different directions taken by the curette to ensure a reasonably smooth surface. The pocket is then lavaged with dilute Chlorhexidine rinse to remove all loose debris. You may gently blow a stream of air and/or water into the pocket to allow visualization of the root surfaces and verify adequate cleaning. Any remaining specks of calculus should be removed. If the root surface appears to be clean, you are now ready to place the Doxirobe gel.

All the following diagrams courtesy of and with the permission of Dr. Ed Eisner, from Holmstrom, Frost, and Eisner, Veterinary Dental Techniques.



Doxirobe gel is then gently syringed into the bottom of the prepared pocket until it just starts to ooze out of the pocket. Your goal is to completely fill the pocket with Doxirobe gel, without over filling the space. A few drops of water on the exposed product will start the gel hardening, and it will eventually product is packed into the pocket,

Step 4. Subgingival cleaning - cont'd

wax as it is packed in the pocket over 30-60 seconds. After the product is packed into the pocket, a gauze sponge may be pressed against the gingival tissues to help force the product into all of the pocket spaces. This will help provide retention of the product in the pocket and also serves to re-appose the gingival tissues in a more normal position. Any smooth blunt instrument may be used to pack the product. Useful instruments include a #7 wax spatula or a plastic filling instrument. Any Doxirobe protruding out of the pocket after it hardens will tend to pull the product out of the pocket. If you overfill the pocket, just remove the Doxirobe and repeat the procedure using a smaller amount. As the Doxirobe dissolves, the periodontal tissues will hopefully re-attach to the cleaned surface, eliminating the periodontal pocket.

Step 5. Polishing

Polishing of the tooth surfaces removes small defects and irregularities that occur during the cleaning process. Smoothing the surfaces decreases plaque retention and slows the formation of calculus. Polishing is accomplished using a prophy angle on a slow-speed handpiece, and a fluoridated prophy paste. The RPM should be kept between 1-3000, and the prophy cup should be used with a light circular motion. Some electric micro-motor slow speed motors are capable of turning in excess of 42,000 RPM, which is too fast for safe polishing. When run at the correct speed of 1-3000 RPM, the prophy cup can be comfortably “stalled” by pressing the cup against a gloved fingernail. Gentle pressure will allow the prophy cup to “splay” slightly under the gum line. To avoid thermal damage, be sure to not polish any single for more than 15 seconds at a time.

Step 6. Sulcus irrigation/lavage

After cleaning and polishing, debris will be present in the gingival sulcus. This debris should be removed to prevent irritation of the soft tissues. Water, saline, or dilute Chlorhexidine are all effective irrigants. The use of a the air-water hand piece or curved tip syringe allows you to direct the irrigant gently into the gingival sulcus, effectively removing loose calculus and polishing materials.

Step 7. Fluoride application

Flouride application serves the strengthen the enamel and helps decrease sensitivity associated exposed dentin and/or root surfaces. Although the incidence of caries is much lower in veterinary patients than in humans, fluoride use may help decrease the incidence of caries. The use of fluoride is somewhat controversial in veterinary dentistry. The author feels that there is very little down side to using fluoride, other than a few additional minutes of anesthetic time. My preference is to use fluoride as part of a complete dental cleaning procedure. There are several different types of fluoride products available, as listed below.

- Acidulated Phosphorylated Fluoride (PH= 3)
- Stannous Fluoride (tin decreases sensitivity, PH=3)
- Sodium Fluoride (neutral ph)

Note the acidic Ph of the first two products. Sodium fluoride is occasionally dispensed for home use, and has a neutral Ph. The author prefers the use of the acidulated, phophorylated fluoride foam (Flurafom-Virbac). The fluoride product is painted on the teeth using a cotton swab, left on for 3-5 minutes, then wiped off to prevent gastric irritation. The patient should not be allowed to swallow large amounts of any acidic fluoride product. **Do not rinse** the fluoride off or you will negate its activity.

You might consider offering clients a “**juvenile prophy**” at the time the patient is spayed or neutered. The procedure involves simply polishing the teeth with a fluoride polishing paste, rinsing the polishing paste off, followed by the application of a fluoride product. The fluoride remains on the teeth for a few minutes while the patient is being prepped for surgery and is then wiped off. This procedure involves only a few minutes of technician time.

Step 8. Complete charting

At this point you are ready to chart all pathology present in the mouth. Remember that most patients will have some pathology present in their mouth. Anything out of the ordinary should be recorded for future reference. Be sure to show the chart to the owner so they can appreciate the extent of disease present in their pet. Adequate documentation of dental pathology requires the use of full-page dental charts. Dental labels or ink-stamped dental charts to not provide the room required for meaningful dental records. Full page dental charts become particularly useful as serial charts are accumulated during the life of the patient. Changes in dental health can be easily tracked by referring to earlier charts of the same patient. Several examples of excellent dental charts are available to you through the website of the American Veterinary Dental college. To download these files is PDF format, go to www.AVDC.org > information for veterinarians> information for registered applicants> dental charts. You can download these charts and E-mail them to your graphic artist for modification. See the last page of this handout for an example of a completed dental chart.

Examples of common abnormalities that should be charted include:

- Periodontal pockets over 3mm in dogs and 1 mm in cats
- Furcation exposures and their grade
- Fractures/ exposed dentin/ exposed pulp
- Loose teeth
- Gingival Hyperplasia
- Root exposure
- Mobility
- Attachment Loss
- Missing teeth
- Draining Tracts
- Oral Masses
- Oral ulceration/ kissing lesions
- Traumatic occlusion
- Malocclusion if present, and type
- Grade of gingivitis
- Grade of calculus

Tooth Numbering – Triadan system

The modified Triadan system provides a consistent method of numbering teeth across different animal species. The system is based on the permanent dentition of the pig, which has 11 teeth in each quadrant - three incisors, one canine, four premolars and three molars. The grand total is 44 teeth. The same framework exists for all species, but other species may have missing teeth from evolution and, in these cases, the numbers take this into account as long as certain rules are followed.

The **first digit** of the modified Triadan system denotes the quadrant:

Right upper permanent = 1	Right upper deciduous = 5
Left upper permanent = 2	Left upper deciduous = 6
Left lower permanent = 3	Left lower deciduous = 7
Right lower permanent = 4	Right lower deciduous = 8

The second and third digits denote the tooth position within the quadrant, with the sequence always starting at the midline.

Step 8. Complete charting - cont'd

The system relies on definite landmarks - the so-called **“rule of fours and nines”**. The canine teeth are always Number 4 when present. The first molars are always number 9 when present. In addition, the carnassials are always the upper fourth premolars and lower first molars. In cats, where tooth numbers are reduced, the use of the carnassials as landmarks will help considerably.

Another valuable tool for documenting pathology is a digital camera. When combined with a photoquality inkjet printer and photo-quality inkjet paper, high quality images can be produced which show the owner in graphic detail what is present in their pet's mouth. Before and after photos are very helpful for demonstrating the value of your care to owners. Custom reports are easily generated using wordprocessing templates and are equally valuable in all departments of a veterinary practice.

Step 9. Radiographs

Dental radiographs are an essential diagnostic tool in veterinary dentistry. Eighty percent of clinically relevant dental anatomy is not visible to the naked eye, and so can not be visualized without the use of dental radiographs. It is simply not possible to practice quality dentistry without the use of dental radiographs. Trying to practice dentistry without using dental radiographs is like trying to treat ear disease without an otoscope, or diabetes without blood glucose measurements.

All abnormal areas that were noted on the chart should be radiographed and evaluated for pathology. Owners love to see dental films from their pet, and will often comment on how severe the radiographic lesions are. There is no better investment for a small animal practice than a dental X-ray unit.

Step 10. Treatment Plan

The next step is to develop your treatment plan for any additional treatment required on the patient. Most patients will require some additional treatment beyond the basic cleaning. Remember to include any needed medication and to charge appropriately for your professional time and materials. Do not forget anesthesia time, additional monitoring, assistant's time, surgical pack and suture, and a fair fee for doctor's time. Present your treatment plan to the owner with conviction, making it clear that you think this is in the pet's best interest.

If your schedule allows, try to complete treatment during the same anesthetic episode. In some cases, you can stage the treatment into two sessions, or have the patient come back in 1-2 weeks to complete treatment. Severely diseased gingival tissues can benefit from 1-2 weeks of oral antibiotics prior to oral surgery. As you gain dental experience, you will learn to budget an average of 1-2 hours per patient for additional treatment over and above the basic cleaning.

Step 11. Home care

At some point during the dental cleaning process, you should go over home care options with the owner, preferably on their own pet. If the pet required only an uncomplicated cleaning, you should go over home care at the time of discharge. If there were any areas treated that might be painful (extractions, sutures, root planing) or Doxirobe gel was placed, home care should be delayed while healing occurs. In these cases, the author will have the owner bring the pet back for a free re-check exam in 3-4 weeks, at which time the owner is educated on their home care options. A capable technician can perform the recheck exam and home care demonstration.

Keep a box with your preferred home care items in it, and take the box into the exam room and demonstrate the products on the pet in front of the owner. If you can't use a product on the pet, it is probably unrealistic to expect the

Step 11. Home care - cont'd

owner to do so. Try to avoid putting pressure on the owner, but rather let them know that anything they can accomplish will be of benefit. Educate the owner that the more they are willing to do, the less you will have to do. Find out what their level of participation is, and compliment them on being willing to do **anything**.

Products with proven efficacy have earned the seal of the Veterinary Oral Health Council (VOHC), which certifies products in an impartial manner. To earn the VOHC seal, a product must be voluntarily submitted by the manufacturer for review, and demonstrate significant patient improvement in rigorous standardized trials. A current list of approved products is available online at: www.vohc.org

Available home care modalities include:

1. **Brushing** - Disruption of plaque is the gold standard for home care, and brushing is the best way to accomplish this goal. The author prefers the CET dentifrice products, which come in a variety of flavors. To be effective, brushing needs to be done at least every other day. Plaque begins to mineralize into calculus after 48 hours. Once mineralized the accumulations become more resistant to mechanical removal. Studies have shown that brushing every other day serves to maintain periodontal disease in a constant state, while daily brushing can actually improve the health of the gingival tissues. Recommend twice daily brushing, and hope that the clients will do it half that often.
2. **Rinses** - A number of Chlorhexidine rinses are available for use in veterinary patients. The CET Oral Hygiene Rinse by Virbac is one example. Chlorhexidine is a very effective oral antiseptic with a good spectrum of activity and no bacterial resistance. It is effective at reducing the bacteria responsible for plaque production, and has residual action that can last up to 12 hours. These products are simply squirted into the mouth 1-2 times daily. Some dogs and many cats object to the taste of the Chlorhexidine rinses. Most owners find these products easier to use compared to brushing their pet's teeth.
3. **Gels** - Zinc Ascorbate (Maxiguard) gel has an antibacterial effect and helps promote tissue healing. This product is very useful during the healing phase after periodontal treatment. Because there is no flavor associated with this product, it is readily accepted by dogs and cats. A small amount (pea sized) of the product is simply rubbed on the gums on both sides of the mouth 1-2 times daily.
4. **Oxyfresh rinse** - some veterinary dentists recommend the use of Oxyfresh, which can be placed in the drinking water. A cap full of the oral rinse is added daily per quart of drinking water. The active ingredient in Oxyfresh is Chlorine Dioxide, which has been shown to reduce certain Sulphur containing compounds that are associated with periodontal disease and malodor.
5. **Chews** - a number of different chew type products exist. All serve to mechanically disrupt plaque and/or calculus. The author recommends Kongs, rawhides, and “Greenies”. Many cats enjoy the small feline greenies. Most dogs accept the CET enzymatic rawhide chews. Some cats will chew on the CET brand oral hygiene chews. Clients should be advised to monitor all chew toys and products closely to make sure the pet is not swallowing large pieces of the product. All chew toys should be supervised. If a pet shows a predisposition toward swallowing larger pieces of any chew toy, alternative choices should be considered. Clients should be advised to avoid any chew products that are harder than teeth. These include whole bones, cow hooves, pig ears, and hard Nylabones, all of which are associated with a large number of fractured teeth.
6. **Foods** - There are a number of dental-specific diets available. Two general strategies are employed in these products; a fiber mesh in the food that rubs plaque away as it is eaten and the addition of Phosphorous-containing compounds to the surface of the product. T/D by Hills contains a fiber mesh that scrubs the teeth as the food is consumed. Some patients object to the size of the kibble in T/D. Most IAMS/Eukanuba products now contain a polyphosphate coating that slows the mineralization of plaque into calculus. This helps keep the plaque soft, allowing mechanical removal by chewing and/or brushing. Friskies Dental Diet and Tartar-chek biscuits contain the same ingredient. Royal Canin has a dental preventative diet that employs both mechanisms, fiber and polyphosphates, with the addition of a green-tea polyphenol extract that has reported antibacterial properties.

Step 11. Home care - cont'd

7. **OraVet** - OraVet gel is a wax-like material that is applied to the dentition after a cleaning, adhering to the tooth surface through electrostatic charge. The product reportedly peels in thin layers, taking with it any plaque that has become attached to the surface of the product. Initially, a professional strength form of the product is applied, which lasts for two weeks. OraVet then requires weekly application by the owner to maintain additional layers, which peel away over time. In two non-peer reviewed studies, the manufacturer has demonstrated “efficacy” in plaque reduction. “Efficacy” is demonstrated when a product shows its intended effect when used under ideal conditions (i.e.-a controlled setting with application by trained personnel) “Effectiveness” is when a product shows its intended effect when used in the real world by normal clients. OraVet has yet to show “effectiveness”, and has not been submitted for approval by the VOHC. One place to consider using this product is post-operatively in oral surgery patients. Since regular home care may be difficult during the healing phase, the product may help decrease plaque accumulation until regular home care can be instituted.
8. **Periodontal vaccine** - A novel canine periodontal vaccine should be introduced by Pfizer in 2006. The vaccine is a trivalent bacterin containing the antigens of the three most common periodontal pathogens of the *Porphyromonas* spp. Many bacterial species in the genus *Porphyromonas* have been implicated in periodontal disease in dogs. The three species chosen for the vaccine are widely distributed across the phylogenetic spectrum of the genus. Research studies in mouse-models and canine-models have been very encouraging. The vaccine is being released with a provisional FDA license. Provisional licensure means that safety for the product has been demonstrated, and there is “reasonable evidence that the product will be effective when used as directed”. You might consider using the vaccine in affected patients and breeds at-risk for developing periodontal disease. One interesting twist is the likely availability in the near future of a genetic marker test for predisposition to periodontal disease. A practitioner might want to consider testing at-risk dogs and using the vaccine in those individuals shown to be genetically predisposed to the development of pathology. The full effectiveness of the vaccine will not be known until it has been in use for 1-2 years.

Step 12. Schedule the next appointment

Let the client know the next time you or your staff should be seeing their pet, and make sure your reminder system is in place and working. The next appointment might be a one month re-check to see how surgical extractions have healed, or it might be a 6-month re-check in a periodontal patient to assess how home care is working. Consider having your staff perform free re-check exams to assess healing and go over home care. Whenever you go over home care for that patient, plant the seed for when the next oral exam should take place. This can vary from patient to patient. A dog with minimal calculus accumulation might need annual evaluation, while another patient with chronic periodontal problems might need to be seen every few months.