



# DENTALAIRE

Meeting and Exceeding the Needs of Veterinary Dentistry since 1988



## Basic Periodontal Treatment in Dogs and Cats

*Presented by:*

**Dentalaire**

Tony M. Woodward DVM, Dipl. AVDC  
5520 N. Nevada Ave. Suite 150  
Colorado Springs, CO 80918  
(719) 536-9949  
tw@wellpets.com  
www.wellpets.com



[www.DentalaireProducts.com](http://www.DentalaireProducts.com) | 800.866.6881

Dentalaire Products | 17742 Mitchell North, Suite B Irvine CA 92614

[info@dentalaireproducts.com](mailto:info@dentalaireproducts.com)



Periodontal disease results from the action of oral bacteria in concert with the host response to that infection. Both are thought to contribute substantially to the creation of periodontal pockets, which are defined as pockets deeper than 1 mm in a cat or 3 mm in a dog. Pocket depth is measured by gently inserting a periodontal probe into the gingival sulcus (under the gum line) and measuring the distance between the bottom of the periodontal pocket and the gingival margin. Periodontal probes have marks that facilitate measurement, and should be placed into the pocket with very light forces to avoid falsely increasing the measurement.

Once a periodontal pocket forms, it serves as a hiding place for food, plaque, and calculus accumulation. If allowed to continue, the process results in loss of supporting bone and destruction of the attached gingiva. Eventually the tooth will become mobile, but the problem has usually gone on for many months or years before this occurs. A frequent clinical picture is the small dog that comes in for a dental cleaning procedure every year, and every year there are a couple more “loose teeth” to be extracted. What has occurred in many cases is that existing periodontal pockets have not been recognized or treated, and a year down the road they become severe enough to result in mobility of additional teeth. An astute clinician recognizes the need to identify and treat these pockets, which are located under the gum line and out of sight.

An important distinction is the difference between “open” and “closed” root planing. When a periodontal pocket measures 4-5 mm deep or less, the pocket can be adequately cleaned without opening a surgical flap. When a pocket is over 5 mm deep, it cannot be adequately cleaned without surgically opening the site with a gingival flap, which provides improved exposure for cleaning, bone contouring, and possible placement of graft materials. When a surgical flap is employed, the procedure is termed “open root planing”, and that discussion is beyond the scope of this article. Open root planing is a technique-sensitive procedure that requires specific training for success.

Entire human dental textbooks are devoted to periodontal therapy. A complete explanation of all the facets of periodontal disease and modes of treatment is not possible here. The following basic periodontal techniques can be used on a daily basis in most veterinary hospitals, and may be adapted to many different situations.

These techniques are:

1. Closed Root Planing (with or without placement of a perioceutic agent)
2. Gingivectomy/gingivoplasty

#### Closed Root Planing (+/- placement of a perioceutic agent)

This technique is used when a periodontal pocket measure 4-5 mm deep or less. Once the pocket's depth is defined, a dental radiograph is obtained of the affected area. Never undertake any type of root planing without obtaining a dental radiograph of the area. In many cases, the pathology is much more severe than expected, and your treatment options will be modified. It is not unusual for a perceived small pocket to actually extend to the apical area of the root, resulting in an endodontically compromised tooth.

Closed root planing is usually presented as being comprised of three distinct steps:

1. Root scaling (removal of calculus and diseased cementum from the root surface)
2. Root planing (smoothing the surface)
3. Subgingival curettage (removal of diseased soft tissues from the inside lining of the pocket).

In actual practice, these steps occur simultaneously as the pocket is treated. The goal of the procedure is to remove all foreign material and diseased cementum, leaving a reasonably smooth surface that will allow the soft tissue to re-attach to the tooth surface.

The instruments used for root planing are ultrasonic scalers and hand scaling instruments. Usually, a combination of the two is used to treat the pocket. Much of the procedure can be accomplished by first using an ultrasonic scaler, then touching up with hand instruments. Ultrasonic scalers are being increasingly utilized for root planing, requiring

the use of special periodontal tips for the scaler. These perio “thin tips” are designed for use under the gum line, and are available for most ultrasonic scalers on the market. When using an ultrasonic scaler subgingivally, use only the side of the scaler tip and keep the forces very light to avoid iatrogenic trauma. It is important to use a lavage fluid integrated into the scaler tip to provide subgingival lavage. Dilute (0.12%) Chlorhexidine rinse is ideal for this purpose. Commonly encountered acronyms for the use of ultrasonic instrumentation subgingivally are PerioBUD (Periodontal Bacterial Ultrasonic Debridement) and UPL (Ultrasonic Periodontal Lavage).

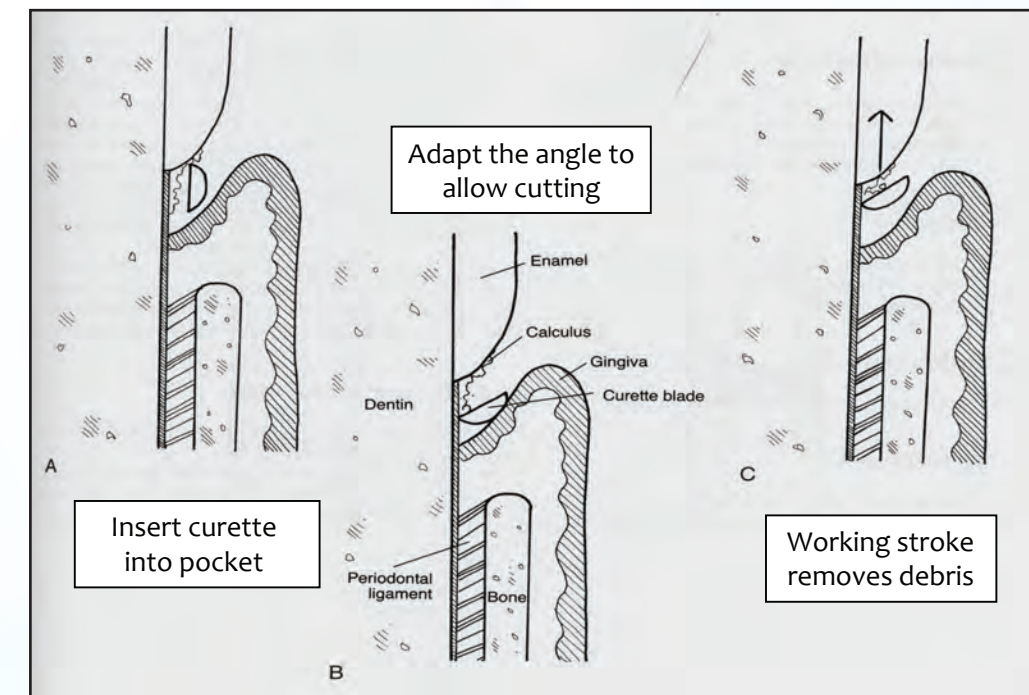
Hand scaling instruments are divided into two types: scalers and curettes. Scalers have sharp tips, are triangular in cross-section, and are utilized above the gum line. Curettes are hand scaling instruments that have been designed for use under the gum line. Curettes have a blunt “toe” and a curved back, which makes them less damaging under the gum line. The curette is placed into the periodontal pocket, adapted to the root surface, and pulled out during the working stroke. Multiple overlapping strokes and multiple directions result in a smooth root surface, free of plaque, calculus, and toxic material. The desired end point is a fairly smooth surface with all calculus removed. The root surface can often be visualized by gently directing the air from an air/water syringe into the sulcus. This flares the gingival tissue away from the tooth, blows away any fluid, and allows visualization of the treated surfaces.

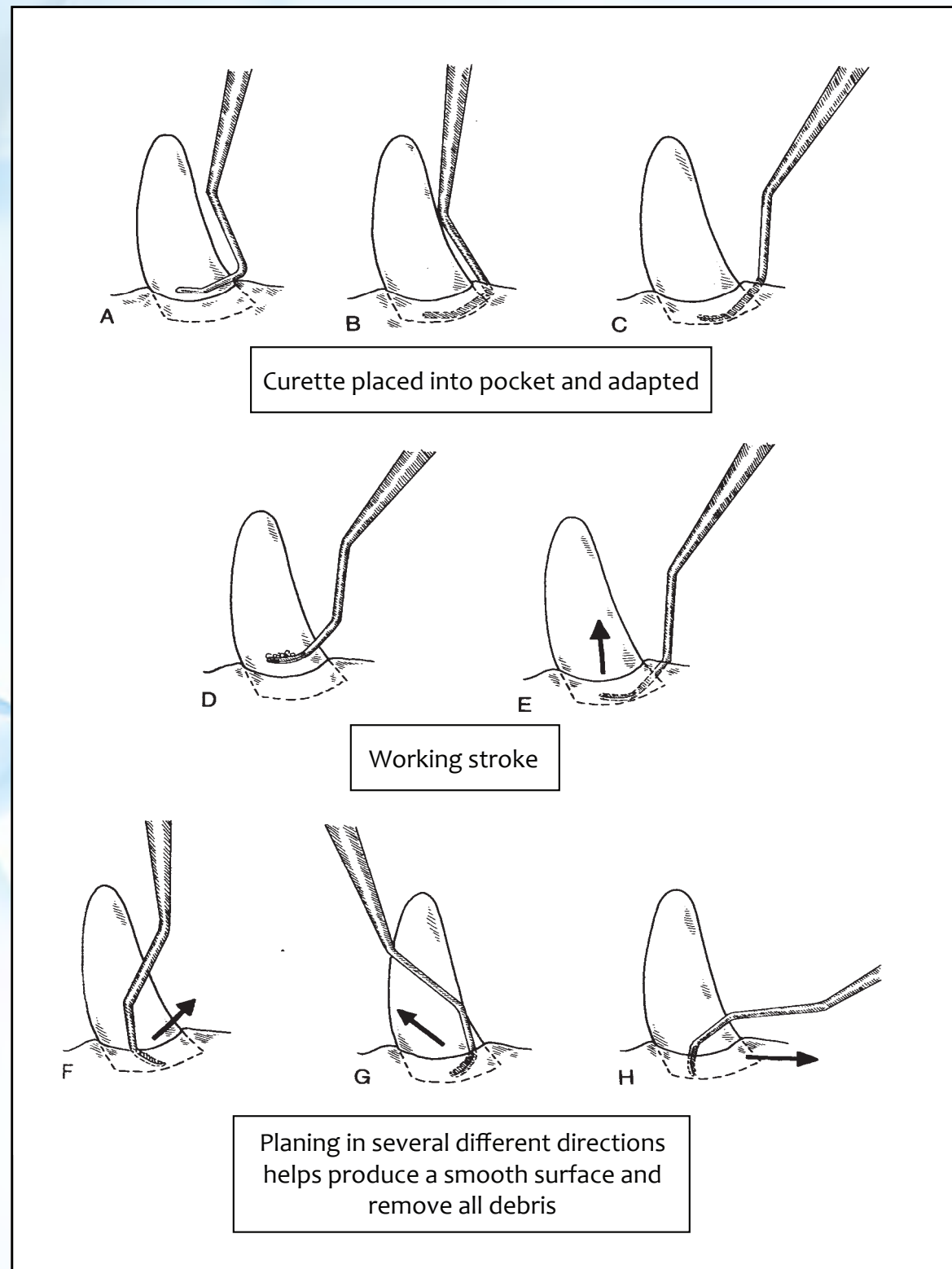
After the pocket is cleaned, you can consider the use of some type of medicament placed into the pocket. A variety of such products exist, with one of the most common being Doxirobe gel. Doxirobe gel is a slow-release form of Doxycycline that fights infection, inhibits tissue destruction, and helps keep debris and plaque from filling up the defect. Doxirobe gel combines an absorbable polymer with Doxycycline powder. The product is placed into the cleaned pocket and packed into place using a #7 wax spatula, plastic filling instrument, beaver tail, or similar blunt instrument. A few drops of water will start the Doxirobe gel hardening, and it will eventually achieve the consistency of candle wax as it is packed in the pocket over 30-60 seconds.

See below for a diagram of closed root planing. Note the different directions taken by the scaler to ensure a smooth surface.

#### Hand Scaling

Illustrations with permission from Veterinary Dental Techniques; Holmstrom, Frost, and Eisner

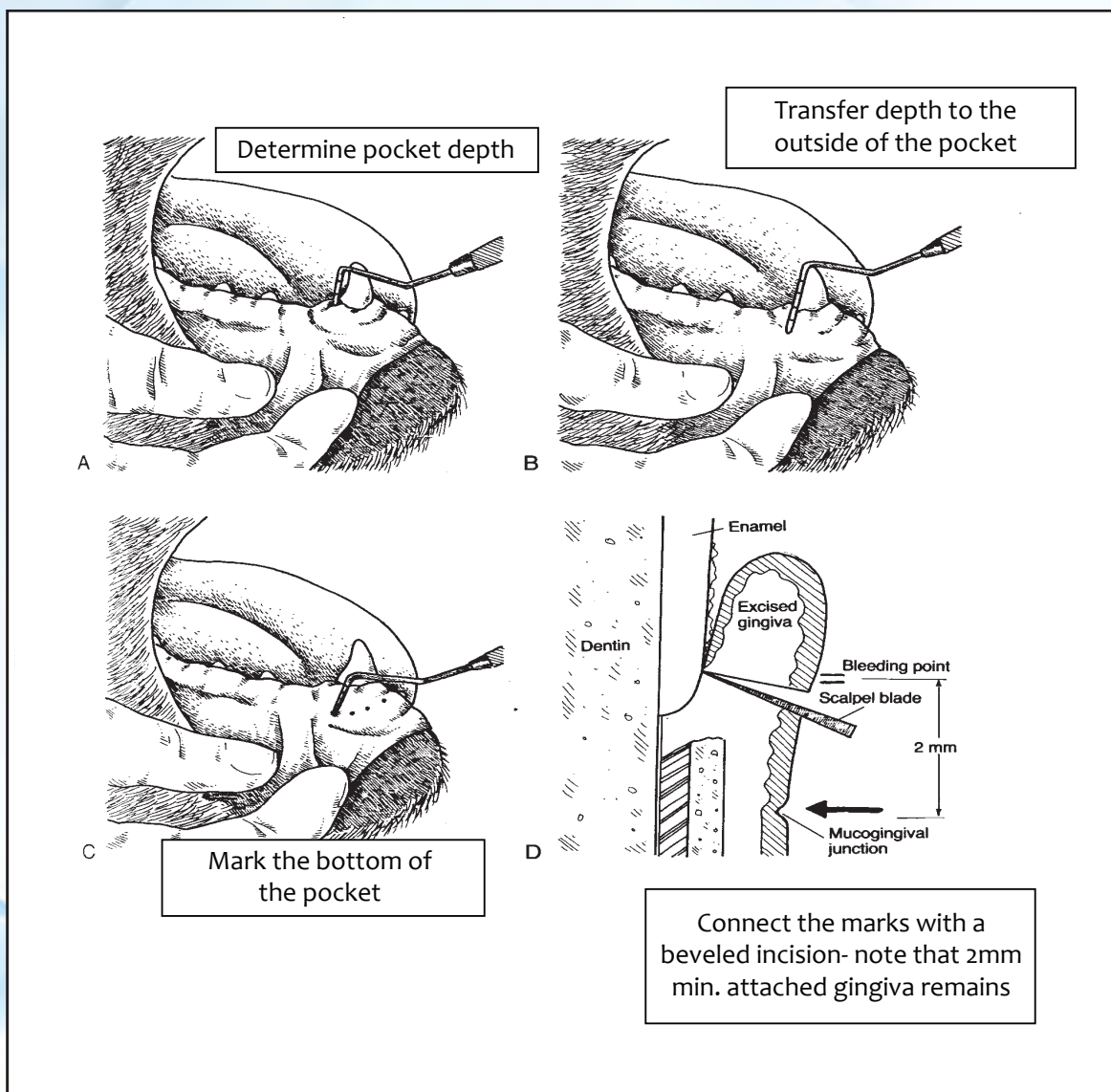




### Gingivectomy

The normal maximum periodontal probing depth is 1mm for a cat and 3 mm or less in a dog. When pocket depth exceeds these numbers, it may be because of tissue destruction (true periodontal pocket) or overgrowth of normal gingival tissue ("pseudo-pocket"). Whatever the cause, the pocket depth must be reduced or the process will continue. When gingival tissues are hyperplastic, the simplest way to remove the pocket is to excise some of the overgrown gingiva. One must take care not to remove all of the attached gingiva, as it provides the primary barrier to bacterial invasion. As long as 2-3 mm of attached gingiva remains after the procedure, the health of the tooth is not compromised. This technique is especially useful in the canine teeth (where there is a large amount of attached gingiva), and in cases of gingival hypertrophy, where the gum tissue is simply overgrown. In both cases ample attached gingiva remains after the procedure.

The procedure is performed by probing along a periodontal pocket and marking the depth of the pocket as you go. Pocket depth may be marked with a dental explorer, making small puncture marks in the overlying gingiva corresponding to the bottom of the pocket. These "bleeding marks" will serve to guide your gingivectomy incision. An incision is then made using a 15c blade or radio-surgical unit to connect the bleeding points. Electro-cautery units should not be used for this procedure as the tissue can necrose further than intended. Laser units are also commonly used for this procedure. Whatever modality is used, take care to bevel the incision approximately 45 degrees, leaving a feathered margin in the edge of the remaining gingiva. The exposed tissues will rapidly epithelialized as the area heals.



#### Recommended instrumentation for basic periodontal procedures

1. Scalpel handle with 15C blades
2. A variety of hand scaling curettes including Columbia, Barnhart, and a selection of Gracey (area specific) curettes
3. Flat and conical sharpening stones for maintaining the hand scaling instruments
4. Thin tips for your specific ultrasonic scaler
5. Dental explorer for detection of small deposits on root surfaces
6. Periodontal probe with appropriate markings
7. Radio-surgical unit for gingival surgery
8. Dental X-ray unit, film, and chairside darkroom

#### Recommended text books for basic periodontal procedures

1. Veterinary Dental Techniques, Holmstrom Frost and Eisner
2. Veterinary dentistry, Principles and Practice, Wiggs and Lobprise
3. An Atlas of Veterinary Dental Radiology, DH DeForge, DVM FACV, BH Colmery III, DVM, Dipl. AVDC
4. Atlas of Canine and Feline Dental Radiology, TW Mulligan, DVM, Dipl. AVDC, MS Aller, DVM, Dipl AVDC, CA Williams, DVM, Dipl AVDC