



# DENTALAIRE

Meeting and Exceeding the Needs of Veterinary Dentistry since 1988



## Bonded Sealants for Fractured Teeth

*Presented by:*

**Dentalaire**

Tony M. Woodward DVM, Dipl. AVDC  
5520 N. Nevada Ave. Suite 150  
Colorado Springs, CO 80918  
(719) 536-9949  
tw@wellpets.com  
www.wellpets.com



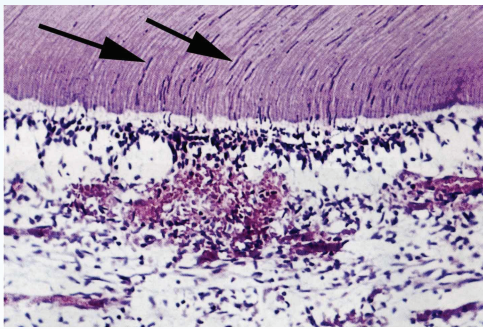
[www.DentalaireProducts.com](http://www.DentalaireProducts.com) | 800.866.6881

17742 Mitchell North, Suite B Irvine CA 92614

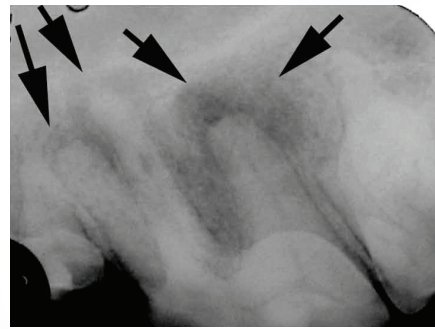
[info@dentalaire.com](mailto:info@dentalaire.com)

Dental fractures are often painful, and treatment can vary, depending on the fracture type encountered. Fractures are occasionally encountered that only involve the enamel. Most dental fractures, however, extend into deeper dental tissues, including dentin and the pulp (nerve) chamber. Fractures with exposed pulp can never heal spontaneously, and should receive endodontic treatment or be extracted. Fractures with exposed dentin and no pulp exposure have historically not been treated, as it was felt they were not a problem. This is simply not true, as exposed dentin is associated with pathology from two different pathways; nerve stimulation and bacterial migration.

The thickness of enamel in dogs and cats varied from 0.1 to 1 mm in thickness. Dental fractures frequently result in the loss of this thin layer of enamel, exposing the underlying dentin that is micro-tubular in structure. The tubules contain fluid that communicates with nerve endings, and anything causing movement of the fluid in the tubules, such as thermal change, results in sensory nerve stimulation. Anyone who has cringed when his or her dentist blows cold air on a sensitive tooth can relate to this phenomenon. Dentinal tubules are also large enough to allow bacteria to migrate directly through the tubules and into the pulp tissues, resulting in an abscessed tooth. The resulting abscessed teeth are some of the more severe endodontic cases seen. Additionally, the rough surface associated with a fracture serves as a plaque-retentive substrate, which fosters calculus formation.



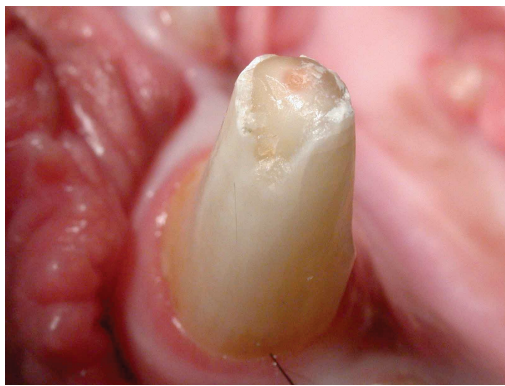
Photomicrograph showing numerous bacteria (arrows) migrating down dentin tubules in association with sepsis of the pulp chamber.



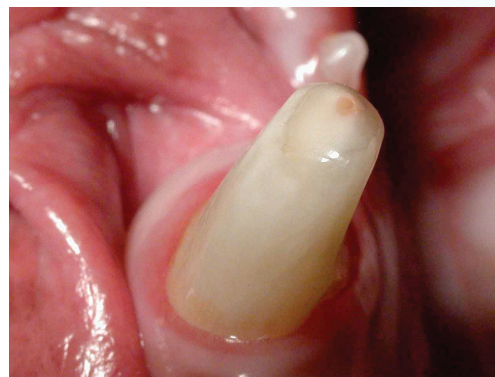
Radiograph of a left upper fourth premolar with a small fracture exposing only dentin. Severe radiographic changes are present in this infected tooth. No exposure of the pulp chamber was present.

A tooth does have some capacity to heal itself when the dentin is exposed, by laying down an “internal patch” of reparative dentin, also known as tertiary dentin. This reparative tissue, when visible on the surface of the tooth, is characterized by a tan to brown color visible in the dentin. Once this process occurs, the fluid filled tubules no longer communicate with nerves and pulp chamber. However, during this healing process, the tooth is uncomfortable and at risk for developing endodontic infection via bacterial migration.

Rather than wait for the tooth to heal itself, a clinician should consider smoothing the fracture site (Odontoplasty), and applying a light-cured acrylic bonded sealant (“Glazing”). This immediately seals exposed dentinal tubules, helps to prevent infection, decreases pain, and speeds up the healing response. The bonded sealants are similar to the sealants placed on children’s teeth, and probably provide around 3-12 months of protection. The sealants penetrate vital (live) dentin to a depth of around 200-400 microns, providing some protection beyond just the surface of the tooth. An overly aggressive chewer, for example a fence chewer, can remove all of the sealant in a very short time. Prevention of the behavior that led to the initial fracture is important for clinical success. A few months after placement of bonded sealants, the tooth will have either healed itself internally or become non-vital. Therefore, all teeth treated with sealants should be re-radiographed in 6-12 months to ensure no pathology associated with death of the tooth or infection is developing. This treatment is generally only done once to each fracture site, and is most useful on fresh fractures. Since the age of a fracture is difficult to determine, the author treats all fractures one time.



Fractured right lower canine tooth prior to treatment.



After smoothing the fracture and applying bonded sealants. Note the smooth surface.

As mentioned previously, this technique is intended for use on vital (live) teeth with dentin exposure. Prior to applying bonded sealants, you should try to determine that the tooth is alive. Typically, a live tooth is not discolored, has no radiographic indications of disease, and transilluminates light evenly when a halogen light source is shone through the tooth. Exam of the contralateral side can provide “normals” for reference.

This technique is very versatile and can be used in a variety of clinical situations. Other indications for the procedure include following odontoplasty performed to eliminate traumatic occlusion, to treat teeth with enamel hypocalcification, and after reducing tight inter-proximal areas to improve access for cleaning. Areas of chronic slow wear, such as occlusal wear from carrying a tennis ball around, have already sealed the dentin tubules in most cases as the wear occurred. This type of wear is characterized by a smooth surface with tan to brown discoloration, and is not typically a candidate for bonded sealants.

#### Materials needed for this process are:

1. High-speed delivery unit with integrated water spray.
2. Oil and Moisture-free air source (dental compressor, canned air, or compressed air tank)
3. Conical White stone burs
4. Latch-key contra-angle for low speed motor
5. Graduated polishing disks and mandrel for low speed handpiece
6. 37% Phosphoric acid etching agent
7. Dentin bonding agent
8. Micro-brushes and disposable wells
9. Unfilled resin
10. Dental light-curing unit

All of the above materials are available from a number of different sources. For your convenience, Dentalaire has gathered most of these materials into a Bonded Sealant Kit #DTP99950. All of the materials can be re-ordered as needed individually. With the bonded sealant kit, all you need is your high-speed dental delivery unit, a curing light, and a latch-key contra angle that fits on your low speed motor in place of the prophylaxis angle.

**The following is a brief description of the process used by the author:**

1. Obtain a radiograph of the fractured tooth, to help determine vitality. This radiograph can also serve as a baseline for follow-up films, and can alert you to any unusual anatomy.
2. Using a conical white stone on a high-speed handpiece, smooth the fractured dentin and enamel, removing all rough edges. The reduction of dental structure should be very conservative, as overzealous reduction weakens the tooth.
3. Briefly use each of the four grades of polishing disks, working from coarse to medium to fine to superfine, further refining and smoothing the fracture site. Be sure to spray the tooth off between grades of polishing disks to remove debris.
4. Apply phosphoric acid etch for 30-60 seconds, then rinse thoroughly and air dry. The air drying should remove all drops of water, but not dry the tooth severely. A desiccated tooth will not bond as well. The etched area will appear to be slightly frosted. Once the etching agent is sprayed off and the tooth is dried, no contamination (water, saliva, blood, etc) can be allowed to touch the site. If contamination occurs, the site should be briefly re-etched. Acid etching improves the bond strength several ways. The dentin is demineralized, exposing the connective tissue for bonding. The dentinal tubules are opened up by this process, which allows the bonding agent to flow down into the tubules, creating the “micromechanical bond” that provides most of the bond strength. Additionally, the “smear layer” of dental debris created during odontoplasty is removed and the surface is roughened which further improves retention.
5. Place a drop of bonding agent (One-Step) into a plastic well, and apply a thin layer to the fracture site using a micro-brush. This layer should be lightly air dried to evaporate the volatile components, and then light-cured for 20 seconds. Remove the thin layer of nonpolymerized bonding agent with a clean gauze sponge, taking care not to contaminate the site with saliva or water.
6. Using a well and micro-brush, place a thin layer of unfilled resin (Fortify) on the fracture site, and light cure for 20 seconds. The unfilled resin bonds to the dentinal bonding agent, and provides a more durable surface. The “glazing” is now complete.
7. Be sure to take follow-up radiographs 6-12 months later. Let the owner know ahead of time that follow-up will be required to ensure that a painful problem does not go undetected.

### Final Thoughts

This article is the last in the series of dentistry articles in this website. I have tried to illustrate, in a short amount of time, the techniques and equipment needed to provide over most of the needed dental care that would ever walk through your door. There are a few key points I would like to re-iterate:

1. 15-20% of gross revenues in a small animal practice should be in the dental department. Most practices average around 3%.
2. Dental disease is painful, however most patients rarely show signs of dental disease other than just “acting older”. Conversely, when you fix their problem, almost all owners comment on their pet “acting younger”.
3. Clients are happy to let you practice improved dental care if you follow the basic steps in marketing dentistry that were covered earlier in this series.
4. The ability to take dental radiographs is an absolute requirement for good dental care, and will soon be the standard of practice. I have now owned and sold four veterinary practices. I believe there is no better investment, which will make you money in small animal practice, than a dental X-ray machine.
5. You need to learn only five basic procedures to deliver 90% of the dental care that comes through your door. These services include a good 12-step cleaning procedure, dental radiographs, surgical extractions, basic periodontal care, and bonded sealants for fractured teeth.
6. A good way to gain these skills is by reading these articles and then attending a lecture/lab in your area. Consider attending the Veterinary Dental Forum, the premier veterinary dental meeting in the world, in Orlando this fall. For information on our classes held in Colorado, send an E-mail to [tw@wellpets.com](mailto:tw@wellpets.com).

### Suggested Reading

1. An Atlas of Veterinary Dental Radiology, DH DeForge, DVM FACV, BH Colmery III, DVM, Dipl. AVDC, Iowa State University Press, Ames IA, 2000
2. Atlas of Canine and Feline Dental Radiology, TW Mulligan, DVM, Dipl. AVDC, MS Aller, DVM, Dipl AVDC, CA Williams, DVM, Dipl AVDC, VLS, Trenton NJ 1998
3. Oral-dental Radiographic Examination Technique. In: Clinics of North America, Small Animal Practice - Dentistry (ISSN 0195-5616). ER Eisner, Holmstrom SE Guest ed. WB Saunders, Philadelphia, September,1998; 28:5:1063-1087."
4. Veterinary Dental Techniques, 3rd ed. SE Holmstrom DVM, Dipl AVDC, , PF Frost DVM, Dipl AVDC, ET Eisner DVM, Dipl AVDC, Saunders, Philadelphia PA, 2004
5. Veterinary Dentistry, Principles and Practice, RB Wiggs DVM, Dipl AVDC, HB Lobprise DVM, Dipl AVDC. Lippincott-Raven, Philadelphia, PA, 1997



# **DENTALAIRE**

DentalAire has been providing our clients with quality products since 1988. Our friendly and dedicated staff understands the needs of today's veterinary practice and are eager to help.

Our full line of products makes it easy to order and saves you time as well as money.

Good people, great service and quality products is what we're all about.

**17742 Mitchell North, Suite B • Irvine, CA 92614**

**1-800-866-6881**

***The Single Source for All Your Dental Needs***

*Learn more at [www.dentalaire.com](http://www.dentalaire.com)*